


PRESENTING CLINICAL SIGNS

History: Recent history of peritoneal effusion. Abdominocentesis revealed a protein-rich transudate.

DATE

8/24/22

ECHOCARDIOGRAPHIC FINDINGS

2D, M-mode, and Doppler study.

PERFORMED BY:

Tom McNeill

Left atrial size is normal. The mitral valve is normal. Left ventricular wall thickness is normal. Left ventricular internal dimensions are normal. Left ventricular systolic function is mildly hyperdynamic. The aorta and aortic valve are normal. Right atrial and right ventricular dimensions are normal. The tricuspid valve is normal. The pulmonary artery and pulmonic valve are normal.

INTERPRETED BY

 Keith Blass, DVM,
 MS, DACVIM
 (Cardiology)

No shunting lesions are visualized. No heartworms are visualized. No pericardial effusion or cardiac masses are seen.

PATIENT

Samuel Mezger

 LA/Ao – 1.48
 IVSd – 5.0 mm
 LVPWd – 5.0 mm
 LVIDd – 12.9 mm
 LVIDs – 6.0 mm
 FS – 53.4%
 RA – 9.7 mm
 LVOT – 1.21 m/s
 RVOT – 1.31 m/s

SPECIES

Feline

ASSESSMENT/RECOMMENDATIONS

Normal echocardiogram

This examination demonstrates no evidence of structural heart disease. As such, no reason for Samuel's peritoneal effusion is appreciated in the image set.

BREED

DSH

No therapy is recommended based on this exam, though diuretic therapy could potentially be indicated based on the underlying cause of Samuel's effusion.

SEX

A recheck echocardiogram is recommended if new physical exam and/or clinical abnormalities suggestive of cardiac dysfunction develop.

MN
AGE

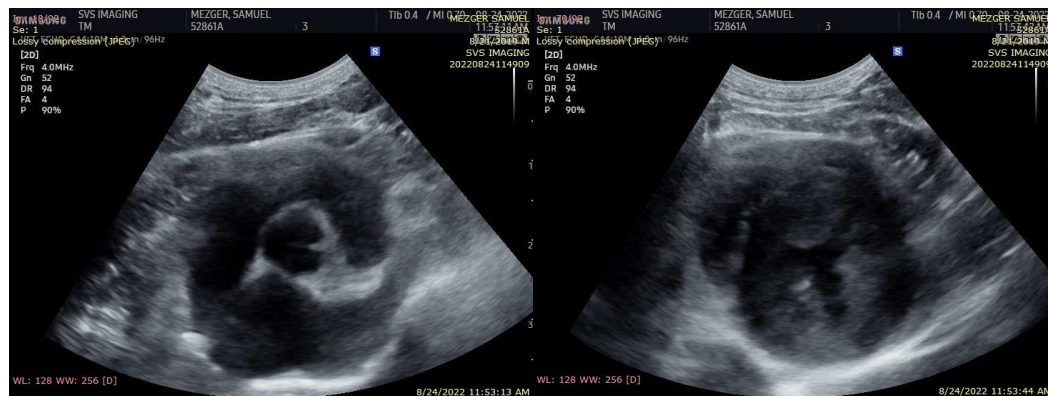
3 y

WEIGHT

6.25 kg

HOSPITAL NAME

SVS Imaging CT



The information and recommendations provided are based on the images presented by the referring veterinarian. No evaluation can be communicated regarding pathology that was not visible in the image/video clips provided.

REFERRING VET

Dr. McDaniel



Thank you for this referral. If the clinical or image interpretation does not parallel your findings or if I can be of any further assistance please contact me.

DATE

8/24/22 **Keith Blass, DVM, MS, DACVIM (Cardiology)**
KeithBlass@gmail.com
631-804-5754

PERFORMED BY:

Tom McNeill

INTERPRETED BY

Keith Blass, DVM,
MS, DACVIM
(Cardiology)

PATIENT

Samuel Mezger

SPECIES

Feline

BREED

DSH

SEX

MN

AGE

3 y

WEIGHT

6.25 kg

HOSPITAL NAME

SVS Imaging CT

REFERRING VET

Dr. McDaniel